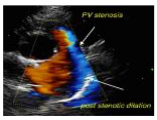
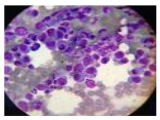
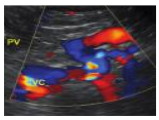

SonoPath.com
1-800-838-4268 info@sonopath.com

PATIENT
Streek Cornell

SPECIES
Canine

BREED
Dachschund

SEX
MN

Age
12 years

WEIGHT

INTERPRETED BY
Remo Lobetti, BVSc, MMedVet (Med), PhD, Dipl. ECVIM

IMAGING PERFORMED BY
Sonya Myers, DVM

HOSPITAL NAME
Lake Emma Animal Hospital

REFERRING VET
Dr Hecker

INVOICE
304109

DATE
4/11/23

PRESENTING CLINICAL SIGNS

History: Chronic pancreatitis and weight loss since splenectomy/GDV.

Physical Examination: N/A.

Urinalysis: N/A.

CBC: N/A.

Serum Biochemistry: N/A.

Radiographic Findings: N/A.

ULTRASONOGRAPHIC EXAMINATION OF THE ABDOMEN

Urinary System

Full urinary bladder with a normal thickness and appearance of the wall. Normal anechoic urine with no sediment or uroliths evident.

Normal trigone area, proximal urethra (0.3 cm), and iliac blood vessels.

Normal iliac lymph nodes (1 cm) with normal shape and echogenic appearance. Ureters not visualized.

Normal size (left 4.1 cm, right 4.3 cm) with increased echogenic appearance, some loss of cortico-medullary differentiation, and normal pelvis and capsule.

Reproductive System

Small hypoechogenic prostate (0.5 cm).

Adrenal Glands

Normal position, echogenic appearance, shape, and size. Left 0.63/0.45 cm, right 0.47/0.63 cm. Small hyperechogenic parenchymal nodule (0.4 x 0.6 cm) in the cranial pole of the right gland.

Spleen

Absent.

Liver

Enlarged with rounded edges, hyperechogenic and nodular appearance, loss of portal markings, and regular curvilinear capsule. Nodules are hypoechogenic and parenchymal. No masses evident.

Gall bladder

Full containing small amount of hyperechogenic sediment. Normal thickness and echogenic appearance of the wall. Normal bile duct (0.2 cm).

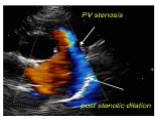
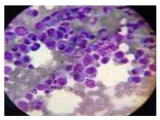
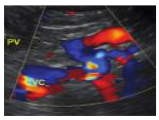

SonoPath.com
1-800-838-4268 info@sonopath.com

PATIENT
Streek Cornell

SPECIES
Canine

BREED
Dachschund

SEX
MN

Age
12 years

WEIGHT

INTERPRETED BY
Remo Lobetti, BVSc, MMedVet (Med), PhD, Dipl. ECVIM

IMAGING PERFORMED BY
Sonya Myers, DVM

HOSPITAL NAME
Lake Emma Animal Hospital

REFERRING VET
Dr Hecker

INVOICE
304109

DATE
4/11/23

Gastrointestinal

Normal appearance of the duodenum, small intestine, ileocecal junction, and colon with no loss of layering, normal wall thickness (duodenum 0.46 cm, jejunum 0.33 cm, colon 0.15 cm) and peristalsis, and no distension of the lumen. Thickening of the gastric wall (0.54 cm) with no loss of layering.

Pancreas

Enlarged (left 0.6 cm, right 1.4 cm) with a hyperechogenic appearance and irregular capsule. Hyperechogenic appearance of the mesentery and fat surrounding the pancreas.

Free Abdomen

Normal mesenteric lymph nodes (1 cm).
No ascites evident.

ULTRASONOGRAPHIC FINDINGS

Primary Findings:

- Pancreatitis.
- Nodular hepatopathy.
- Right adrenal nodule.
- Gastric thickening.

Secondary Findings:

- Age-related renal changes.
- Gall bladder sediment.

INTERPRETATION OF THE FINDINGS & FURTHER RECOMMENDATIONS

Th appearance of the pancreas is consistent with chronic pancreatitis.

Etiologies for the hepatopathy would be nodular regeneration, chronic hepatitis, granulomatous disease, and neoplasia.

Etiologies for the right adrenal nodule would be an incidental non-functional adenoma and emerging carcinoma.

Etiologies for the stomach would be non-specific gastritis, secondary to the surgery (if a gastric pexi was done), *Helicobacter* gastritis, ulcerative gastritis, inflammatory bowel disease, and helminths, with emerging neoplasia a less likely differential diagnosis.

Further assessment would be fecal analysis, cPL/PSL assay, FNA cytology of the liver, and possibly adrenal function testing (ACTH stimulation/LDDS test, if there are compatible clinical and biochemical signs of Cushing's disease) and gastroscopy with biopsies.

Specific therapy would be dependent on an etiological diagnosis.

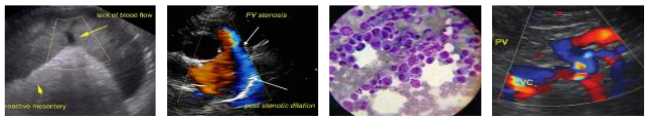

SonoPath.com
1-800-838-4268 info@sonopath.com

PATIENT

Streek Cornell

SPECIES

Canine

BREED

Dachschund

SEX

MN

Age

12 years

WEIGHT

INTERPRETED BY

Remo Lobetti, BVSc, MMedVet (Med), PhD, Dipl. ECVIM

IMAGING PERFORMED BY

Sonya Myers, DVM

HOSPITAL NAME

Lake Emma Animal Hospital

REFERRING VET

Dr Hecker

INVOICE

304109

DATE

4/11/23

IMAGES

Liver

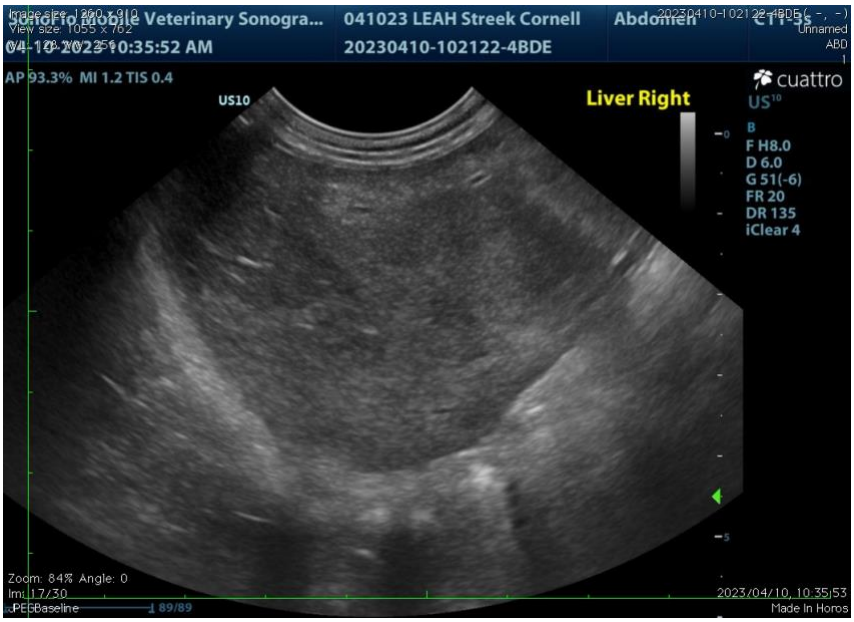

Right adrenal

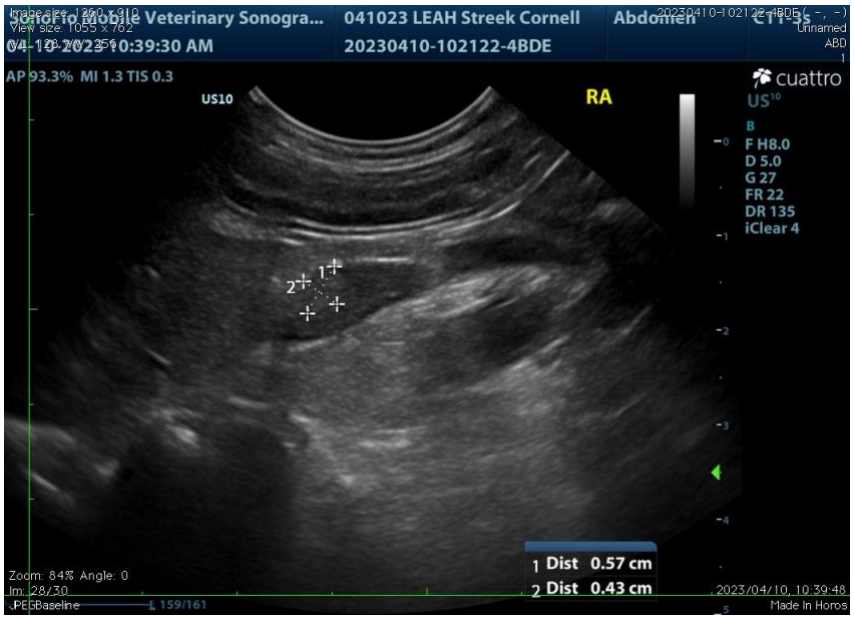

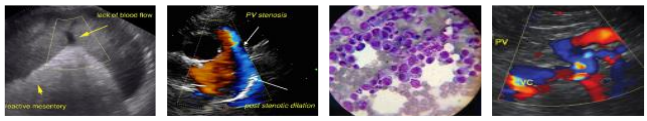

SonoPath.com
1-800-838-4268 info@sonopath.com

PATIENT

Streek Cornell

SPECIES

Canine

BREED

Dachschund

SEX

MN

Age

12 years

WEIGHT

INTERPRETED BY

Remo Lobetti, BVSc, MMedVet (Med), PhD, Dipl. ECVIM

IMAGING PERFORMED BY

Sonya Myers, DVM

HOSPITAL NAME

Lake Emma Animal Hospital

REFERRING VET

Dr Hecker

INVOICE

304109

DATE

4/11/23

Pancreas

Stomach

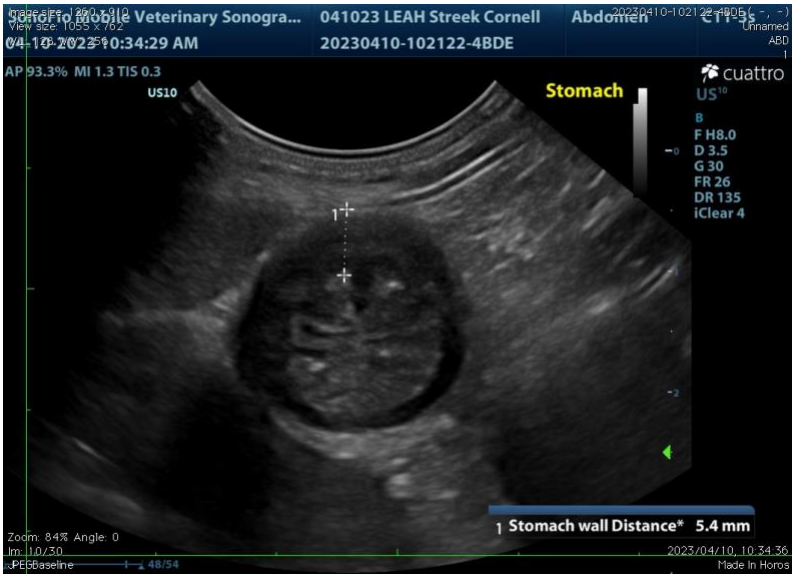

The information and recommendations provided are based on the images presented by the referring veterinarian. No evaluation can be communicated regarding pathology that was not visible in the image/video clips provided.

Thank you for this referral. If the clinical or image interpretation does not parallel your findings or if I can be of any further assistance, please contact me.

Remo Lobetti, BVSc, MMedVet (Med), PhD, Dipl. ECVIM (Internal Medicine)
rlobetti@mweb.co.za